



Unexpected Tissue in The Paratesticular Region: Spleen

Paratestiküler Bölgede Beklenmeyen Doku: Dalak

 İlknur Küçükosmanoğlu¹,  Canan Kocaoğlu²

¹Konya City Hospital, Department of Pathology, Konya, Turkey
²Konya City Hospital, Department of Pediatric Surgery, Konya, Turkey

Makale Tarihleri/Article Dates:

Geliş Tarihi/Received: 30 Mayıs 2023

Kabul Tarihi/Accepted: 25 Ekim 2023

Yayın Tarihi/Published Online:

12 Aralık 2023

Sorumlu Yazar/Corresponding Author:

İlknur Küçükosmanoğlu,
Konya City Hospital, Department of Pathology, Konya, Turkey
e mail: ilknurkukrer@hotmail.com

Açıklama/Disclosure: Yazarların hiçbiri, bu makalede bahsedilen herhangi bir ürün, aygıt veya ilaç ile ilgili maddi çıkar ilişkisine sahip değildir. Araştırma, herhangi bir dış organizasyon tarafından desteklenmedi. Yazarlar çalışmanın birincil verilerine tam erişim izni vermek ve derginin talep ettiği takdirde verileri incelemesine izin vermeyi kabul etmektedirler.

ÖZET

Splenogonadal füzyon (SGF), dalak ve gonadın füzyonu ile karakterize nadir görülen bir konjenital anomalidir. Bildirilen vakaların çoğu, dalak dokusu testis içinde kitle veya paratestiküler kitle şeklinde olan erkeklerdir. SGF tipik olarak sol taraflı skrotal şişlik, sol inguinal herni, skrotal kitle veya kriptorşidizm olarak kendini gösterir. Bu yazıda sol inguinal herni, sağ ve sol inmemiş testisleri olan 8 yaşında erkek hastada ultrasonografide(USG) saptanan ancak karakterize edilemeyen splenogonadal füzyon olgusu sunuldu. SGF'nin preoperatif tanısı genellikle zordur. Çoğu cerrah, eksik malignite cerrahisi riskini azaltmak için radikal tedaviyi seçer. Ürologların ve özellikle pediatrik cerrahların gereksiz, yaşamı değiştiren radikal orşiektomiden kaçınma konusundaki farkındalığı, gelecekteki vakalarda testis koruyucu cerrahiye mümkün kılabilir.

Anahtar Kelimeler: Gonad, neoplazi, testis, dalak, splenogonadal füzyon

ABSTRACT

Splenogonadal fusion(SGF) is a rare congenital anomaly characterized by the fusion of the spleen and gonad. Most of the reported cases are males whose splenic tissue is in the form of a mass or paratesticular mass located in the testis. SGF typically presents as left-sided scrotal swelling, left inguinal hernia, scrotal mass, or cryptorchidism. In this paper, we presented a case of splenogonadal fusion which was detected on ultrasonography(USG) but could not be characterized in an 8-year-old male with left inguinal hernia, bilateral undescended testes. Preoperative diagnosis of SGF is often difficult. Most surgeons choose radical therapy to reduce the risk of incomplete malignancy surgery. The awareness of urologists, and especially pediatric surgeons, to avoid unnecessary, life-changing radical orchiectomy may make testis-sparing surgery possible in future cases.

Key words: Gonad, neoplasm, testis, spleen, splenogonadal fusion

INTRODUCTION

Splenogonadal fusion (SGF) is a rare congenital anomaly characterized by the fusion of the spleen and gonad and defined by the presence of ectopic splenic tissue in the scrotum (1-4). Sometimes mesonephric residues are involved instead of the gonad (5,6). It occurs due to the proximity between the spleen and gonads developing in utero stage (7). SGF is classified as the continuous type with a direct anatomical connection between the spleen and the gonad, or as the intermittent type without a direct connection between these two organs (1,2,4,7). Some cases of continuous type are accompanied by congenital anomalies such as extremity defects, micrognathia, cleft palate, and cardiac defects (4). Most of the reported cases are males whose splenic tissue is in the form of a mass or paratesticular mass located in the testis (7). SGF typically presents as left-sided scrotal swelling, left inguinal hernia, scrotal mass, or cryptorchidism (6). Solid testicular masses in young adults are assumed to be malignant and typically surgical treatment is performed, therefore SGF



Atıf yapmak için/ Cite this article as: Küçükosmanoğlu İ, Kocaoğlu C. Unexpected Tissue in The Paratesticular Region: Spleen. Mev Med Sci. 2023;3(3): 143-146

"This article is licensed under a [Creative Commons Attribution-NonCommercial 4.0 International License](https://creativecommons.org/licenses/by-nc/4.0/) (CC BY-NC 4.0)"

should be differentiated from them (1,2,7). As an economical examination method, ultrasonography (USG) is often used as the first choice for examining testicular masses, including scrotal lesions. However, the ultrasonographic findings of SGF are not characteristic. SGF is often misdiagnosed as testicular tumors, necrotic intestines, multiple testes, etc. Knowing the diagnosis of SGF in advance may prevent unnecessary orchiectomy, especially in testicular tumors (4,6).

In this paper, we presented a case of splenogonadal fusion which was detected on USG but could not be characterized in an 8-year-old male with left inguinal hernia, bilateral undescended testes.

CASE REPORT

An 8-year-old male was admitted to the pediatric endocrinology outpatient clinic due to his overweight. Physical examination of patient revealed swelling in the left groin. Physical examination also revealed that the patient was circumcised and in the normal localization of the urethral orifice. On palpation, it was determined that the testes were not in the scrotum. While the right testis was palpated in the proximal part of the inguinal canal, the left testis was not palpable in the inguinal region. There was no sign of scrotal inflammation. Routine blood tests, abdominal USG, and scrotal color Doppler USG were requested from the patient. An abdominal ultrasound showed a habitual location with standard measurements and a regular aspect of his spleen. On USG in scrotal color Doppler, a 10x8x14 mm testicular tissue with diminished parenchyma echoes and slightly heterogeneous appearance containing millimetric calcifications were observed in the right inguinal canal. Testicular perfusion was normal. The left testis could not be visualized. Two hypoechoic lesions, which may be a lymph node, was detected adjacent to the left inguinal canal, the largest of which was 13x15x30 mm in size, with hilar blood supply and two adjacent lobulated contours. Considering the possibility of a neoplastic testicular or paratesticular lesion, alpha-fetoprotein, human chorionic gonadotropin, and lactate dehydrogenase levels were measured and found within the normal range. Routine blood tests were also within normal limits. Elective inguinal exploration was planned with a clinical diagnosis of left congenital inguinal hernia and bilateral cryptorchidism. Inguinal exploration was performed under general anesthesia. Both testes were found in the inguinal canal and Fowler-Stephens orchiopexy was performed. On left inguinal exploration, the nodular lesion with lobulated contours adhered to the ductus deferens and testis and having its capsule was stripped from the testicular tissue and excised (Figure 1). Since the possibility of the lesion being neoplastic could not be excluded, it was sent to the pathology laboratory for frozen examination. On

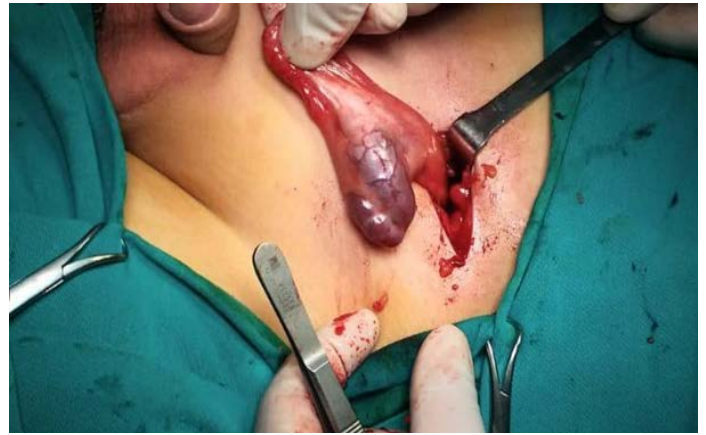

Figure 1. The nodular lesion with lobulated contours adhered to the ductus deferens and testis and having its capsule.

macroscopic examination, nodular lesions of 3x2x1 cm in size, encapsulated, showing lobulation, adjacent to each other in the form of rosary beads were observed. When examined with serial sections, the cut surface is red-brown, solid, and homogeneous (Figure 2). In a frozen examination, splenic tissue in a regular structure, independent of testis and adnexal tissues and without signs of malignancy, was observed and it was reported to the pediatric surgeon. Orchiectomy was not performed because no signs of malignancy were observed. No additional microscopic findings were observed in permanent

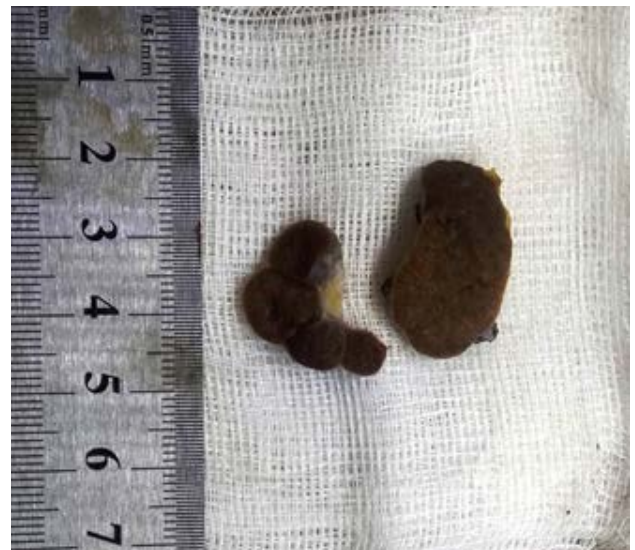

Figure 2. Macroscopic view of an encapsulated rosary-shaped lesion.

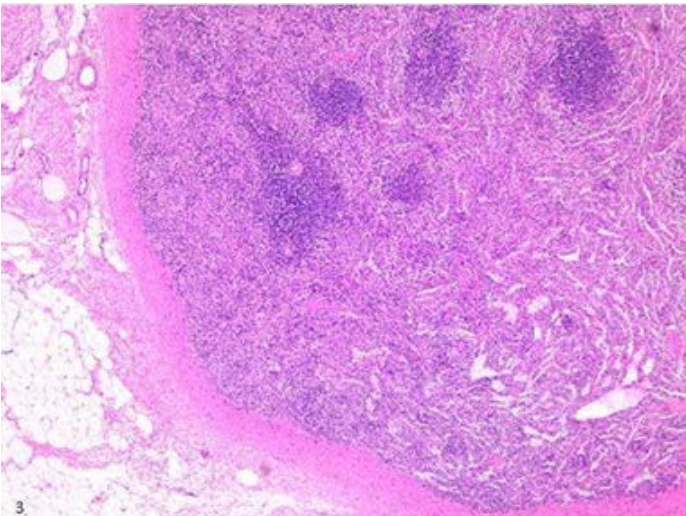


Figure 3. A regular splenic tissue.H&E stain x100

paraffin sections and those observed in frozen sections (Figure 3). The case was reported as intermittent type SGF. The case was discharged from the hospital on postoperative day 2. Ultrasound follow-up performed immediately after the operation showed that the testes were in normal shape and localization, and had good blood flow.

Informed consent was obtained from the patient for whom identifying information is included in this article.

DISCUSSION

Splenogonadal fusion was first described by Bostroem, a German pathologist, in 1883. Continuous SGF accounts for 55% of cases, intermittent SGF accounts for 45% of cases (2,4,8). In half of the reported cases, the age is less than 10 years, and 82% of the cases occur in patients under 30 years of age. SGF occurs in 98% of cases on the left side and is 16 times more common in males than females. This difference is presumed to be due in part to the difficulty of evaluating female gonads with a physical examination. Cryptorchidism is the most common associated anomaly observed in 31% of cases. Intermittent SGF is rarely associated with other congenital malformations. Compared to the intermittent type, continuous type SGF carries a five-fold higher risk in terms of associated anomalies such as peromelia, micrognathia, cardiac defects, cleft palate, and spina bifida (2,3,5,7). The reason for this comorbidity may be that active development of the limb bud and mandible occurs at the same time with SGF at the 5th and 8th weeks of pregnancy. Less common comorbidities include cleft palate, Moebius syndrome, hypospadias, osteogenesis imperfecta, persistent Mullerian canal syndrome, Potter syndrome, gastrointestinal

malrotation, anal stenosis, and transverse testicular ectopia (5,6). Our case was intermittent type SGF, and in our case, only cryptorchidism and inguinal hernia were present among the anomalies mentioned.

Splenogonadal fusion is typically diagnosed incidentally during surgery to treat inguinal hernia and/or cryptorchidism, the two most frequently associated anomalies. Inguinal hernia repair is one of the most common surgical procedures performed in children worldwide. Inguinal hernia is a relatively common surgical problem in children, with a reported incidence ranging from 0.5 to 4.5%. Clinically, it is almost impossible to diagnose splenogonadal fusion. It may be misdiagnosed as a testicular or epididymis tumor, thus leading to inappropriate surgical decisions (6). If we look at paratesticular lesions, we see that the majority of them are benign and usually cystic. The reason why paratesticular solid lesions cannot be simply ignored is due to the possibility of sarcoma. The most common malignant lesion of this area is rhabdomyosarcoma that occurs before adulthood. These are usually larger than benign lesions and more heterogeneous in imaging. Given that SGF can be managed conservatively, a diagnosis should be aimed before orchidectomy, but this is difficult for intra-testicular SGF (7). Typically, the diagnosis is pathological (1,3,7,8). Benign mimics other than SGF include segmental infarction, hematoma, infection, epidermoid cyst, adrenal rest, sarcoidosis, and sex cord-stromal tumors (2).

Scrotal USG may not provide enough accurate information before surgery, sensitivity and specificity are not high due to the variety of sonographic features. The use of contrast-enhanced USG to diagnose accessory perisplenic tissue is well defined and the key finding is contrast retention in the delayed phase (7). In addition, with USG, the connecting cord between the spleen and the ectopic testis can be visualized in continuous form (3). Technetium-99 m splenic scintigraphy has been used to diagnose very few cases preoperatively and to identify accessory splenic tissue (2,3).

A magnetic resonance image is often the first choice to detect the position and shape of the testes and rule out other congenital anomalies. It is reliable and accurate in detecting/excluding a testicular or scrotal lesion, localizing the lesion, and distinguishing between intra-testicular and extra-testicular lesions. In addition, by using different arrays and applying gadolinium, the scrotal disorder pattern can be characterized and testicular lesions can be classified (4,5).

However, the most useful diagnostic test is surgical exploration. In our case, the frozen section during the operation saved the child from orchidectomy because the mass was in the paratesticular location. SGF is a benign condition. During surgery, the testis can be preserved as the splenic tissue can usually be easily separated from the gonad (4). Therefore, in the presence of a scrotal, testicular, or paratesticular mass,

performing the surgery in a center where frozen can be applied may provide more benefits to the patient.

There is no clear causality between SGF and malignant transformation. Rare cases are likely to develop a testicular neoplasm, as they also present cryptorchidism (3,5).

Splenogonadal fusion is a rare congenital anomaly that should be considered in the differential diagnosis of a solid lower left abdominal or scrotal mass. Preoperative diagnosis of SGF, especially with cryptorchid testis, is often difficult. Most surgeons choose radical therapy to reduce the risk of incomplete malignancy surgery. The awareness of urologists, and especially pediatric surgeons, to avoid unnecessary, life-changing radical orchiectomy may make testis-sparing surgery possible in future cases.

Çıkar Çatışması: Çalışmada herhangi bir çıkar çatışması yoktur.

Finansal Çıkar Çatışması: Çalışmada herhangi bir finansal çıkar çatışması yoktur.

Sorumlu Yazar: İlknur Küçükosmanoğlu, Konya City Hospital, Department of Pathology, Konya, Turkey
e mail: ilknurkukrer@hotmail.com

REFERENCES

1. Bal K, Ermete M, Balcı U, et al. Splenogonadal fusion: A very rare congenital anomaly in the differential diagnosis of a testicular mass. *Turk J Urol* 2014;40:62-4.
2. Alsunbul A, Alsuhaibani S, Al Ali H, et al. Splenogonadal fusion: A rare case report and literature review. *Urol Case Rep*, 2020; 33: 101307.
3. Karray O, Oueslati A, Chakroun M, et al. Splenogonadal fusion-a rare cause of scrotal swelling: a case report. *J Med Case Rep* 2018;12:1-3.
4. Abokrecha A, Almatrfi A. Discontinued splenogonadal fusion and bilateral empty scrotum in an 18-month-old boy. *European J Pediatr Surg Rep* 2017; 5: e1-e3.
5. Chen G, Wang X, Zhao Y, et al. Splenogonadal fusion: a case report and review of the literature. *BMC Urol*, 2021; 21: 1-10.
6. Xiang X, Jiang Y, Liu JX, et al. A rare content of congenital inguinal hernia: A case report of splenogonadal fusion. *BMC Pediatr*, 2019; 1: 1-3.
7. Seager MJ, Alexander S, Muneer A, et al. Splenogonadal fusion: A rare paratesticular lesion and how to recognise it on ultrasound. *Ultrasound* 2020; 28: 54-7.
8. Lakshmanan PM, Reddy AK, Nutakki A. A surprising content of congenital hernia: Complete splenogonadal fusion band. *BMJ Case Rep*, 2014; bcr2014203640.